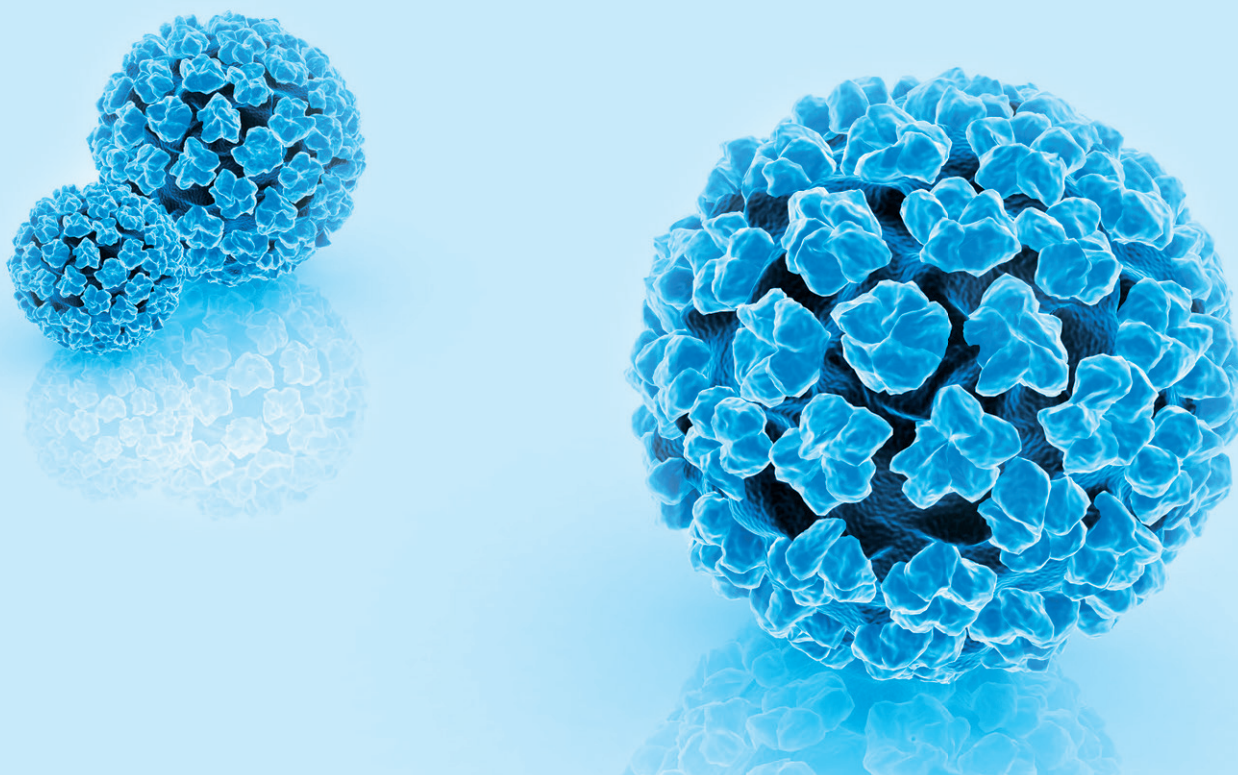




Abviris
Deutschland GmbH

WHITEPAPER

Part 3 | September 2019



Early detection of HPV16-induced tumours:
Guidelines for identifying high-risk patients

Patients with condylomata acuminata

Abviris Deutschland GmbH

Beimoorkamp 6, 22926 Ahrensburg, Tel: 04102 - 677 56 14, Fax: 04102 677 56 15 - info@abviris.de - www.abviris.com

EARLY DETECTION OF HPV16 INDUCED TUMORS: GUIDELINES FOR THE DETECTION OF HIGH-RISK PATIENTS

Patients with condylomata acuminata

The low-risk subtypes 6 and 11 of HPV are thought to be responsible for condyloma acuminata. More rarely, genital warts are linked to increased incidence of cancer in the mouth, throat and anogenital area.

A long-term study of nearly 11.000 patients with condyloma acuminata and 33 years of follow-up has shown that both women and men have a significantly higher risk of developing cancer in the anogenital area as well as in the mouth and throat. Male patients were monitored for an average of 15 years, female patients for an average of 13 years.¹

Almost one percent of the population of reproductive age is affected by genital warts. Warts are usually treated externally and locally, surgically if necessary. Condylomas reappear in over one third of cases after

treatment. The s2k guideline for HPV-associated lesions of the external genital region and anus cite the following causes of recurrence:

- HPV DNA remaining in the surrounding tissue despite therapy
- Infected tissue wasn't removed completely or multifocal infection
- Re-infection by an infected partner²

High-risk HPV subtypes are found in over 33% of genital warts in men and almost 56% of genital warts in women. HPV16 which has high oncogenic potential was the most common type. It was found in 16.5% of genital warts³ (see Figure 2).

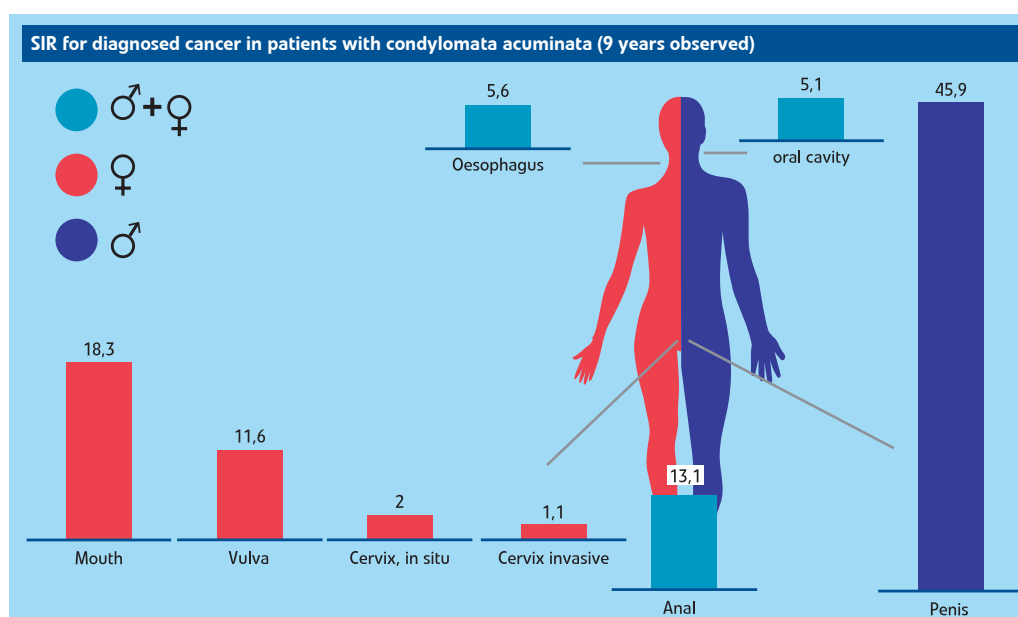


Image 1: SIR within the first 9 years Follow up after diagnosis condylomata acuminata, based on Nordenvall et al. (2006)

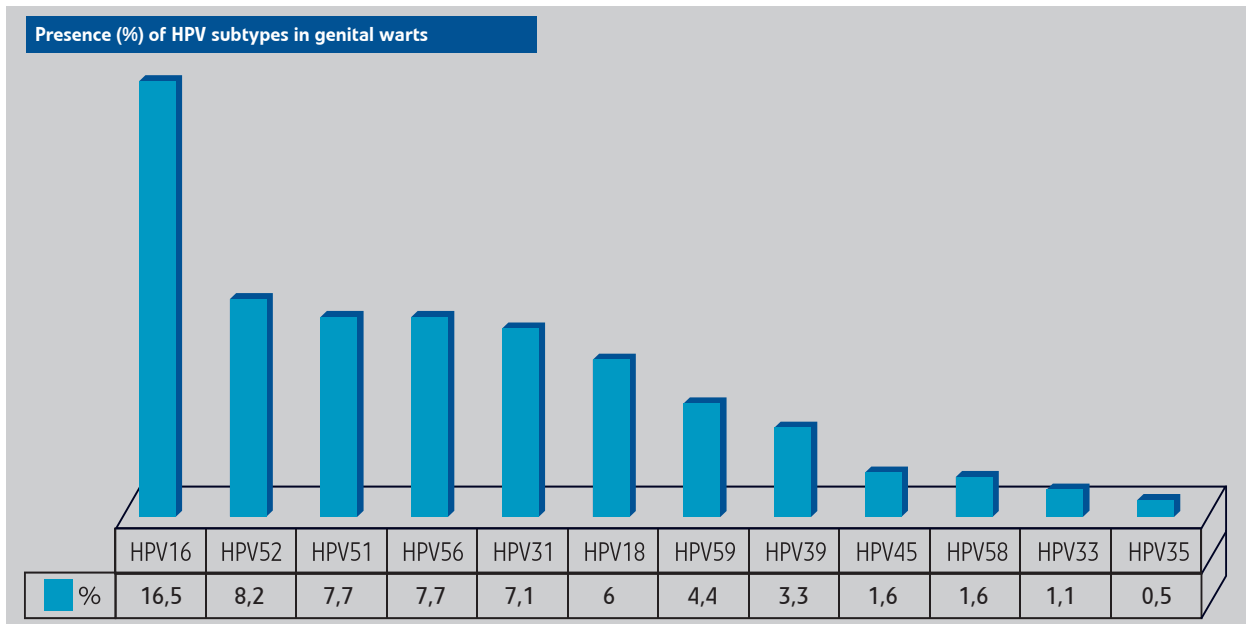


Figure 2: Data based on Kofoed et al. (2014)

References:

1. **Caroline Nordenvall, Ellen T. Chang, Hans-Olov Adami and Weimin Ye:**
Cancer risk among patients with condylomata acuminata; Int. J. Cancer: 119, 888-893 (2006)
2. **s2k Leitlinie zu HPV-assoziierte Läsionen der äußeren Genitalregion und des Anus – Genitalwarzen und Krebsvorstufen der Vulva, des Penis und der peri- und intraanal Haut**
3. **Kristian Kofoed, Carsten Sand, Ola Forslund and Klaus Madsen:**
Prevalence of Human Papillomavirus in Anal and Oral Sites Among Patients with Genital Warts; Acta Derm Venereol 2014; 94: 207–211

©Copyright 2018 - Abviris Deutschland GmbH

Recommendations for the doctor's practice

To improve early detection and prognosis for these patients, we recommend

- Inform patients with condyloma and their partners about the availability of early detection for HPV-induced cancer and recommend regular screening for HPV16-induced carcinoma in the anogenital area, as well as in the mouth and throat.

Read in PART IV: Patients with immunodeficiency